



PATIENT

Ruby Tuesday Beaudoin

SPECIES

Canine

BREED

Brittany Spaniel

SEX

Female Spayed

AGE

12 years

WEIGHT

42.1lbs

INTERPRETED BY

Maggie Machen Lamy, DVM DACVIM (Cardiology)

IMAGING PERFORMED BY

Pamela Harrigan, RDCS

HOSPITAL NAME

Mass Veterinary Services

REFERRING VET

Dr. Masloski

INVOICE

26374

DATE

9/14/22

PRESENTING CLINICAL SIGNS

History: Ruby Tuesday was noted to have a heart murmur in February. Excessive coughing. Pants with labored breathing (very stertorous breathing in exam room highly suggestive of laryngeal paralysis). She is a retired hunting dog. Has lost 6 lbs in the past 3 months. She is eating well but does occasionally vomit white foam. Ruby received her vaccines a few weeks ago and was vomiting for a week afterwards. On exam: NSR, grade III-IV/VI murmur with PMI left apical area, PSS, lung fields clear, pronounced stertorous breathing with brief episodes of cyanosis. BP: 120mmHg x 4. Currently, no medications. *Sedated with propofol and intubated for study.

ECHOCARDIOGRAM FINDINGS

2D, m-mode, color flow and Doppler imaging is available.

Left ventricle: The LV diameter is normal with adequate myocardial function (assessed during recovery). LV wall thicknesses are normal.

Left atrium: The left atrium is mildly dilated.

Mitral valve: The mitral valve is mildly thickened with mild prolapse into the left atrial lumen. Mild eccentric mitral regurgitation with a normal velocity.

Aortic valve/aorta: The aortic valve is normal in morphology and mobility. Normal aortic outflow velocity; laminar flow. No aortic insufficiency.

Right ventricle: Normal right ventricular diameter and morphology indicating no overt evidence of pulmonary arterial hypertension.

Right atrium: Normal RA dimension.

Tricuspid valve: The tricuspid valve appears mildly thickened with septal prolapse and mild tricuspid regurgitation; normal velocity.

Pulmonic valve/pulmonary artery: The pulmonic valve is normal in morphology and mobility. No pulmonic insufficiency. Normal RVOT velocity; laminar flow.

Pericardium/other: No pericardial or pleural effusion noted. No obvious cardiac masses.

Heart rhythm: ECG reveals a sinus rhythm with an average HR of 120bpm.

2-Dimensional Measurements

Ao diam (cm)	2.1
LA diam (cm)	2.6
LA:Ao (Swe)	1.2
IVS thickness (cm)	0.9
LVID diastole (cm)	3.5
PW thickness (cm)	0.9
LVID systole (cm)	1.9
FS (%)	40

Doppler Measurements

PV Vmax (m/s)	0.4
AoV Vmax (m/s)	0.96
MR Vmax (m/s)	4.5
TR Vmax (m/s)	2.2
TR PG (mmHg)	20

INTERPRETATION OF THE FINDINGS

The cause of the murmur is chronic degenerative valve disease causing mild mitral and tricuspid regurgitation. Lack of significant left atrial enlargement indicates the current risk for complication is low. No concurrent issues such as pulmonary hypertension are noted in this study.

Given these findings, the cough is unlikely to be cardiac in origin and primary respiratory causes should be considered. Consider further respiratory work up/treatment (hydrocodone, taper course of steroids, Enrofloxacin, TTW/BAL, etc).



PATIENT

Ruby Tuesday
Beaudoin

Assessment of progression in the future will help predict long term prognosis, which is highly variable at this stage (B1).

SPECIES

Canine

RECOMMENDATIONS

- In a dog without significant left atrial enlargement, no cardiac medications are clearly indicated.
- Omega fatty acid supplementation and mild salt restriction may be of some long-term benefit.
- Anesthetic risk is considered mild if needed. Cardiac protective drug choices (opioid/benzodiazepine premedication, propofol or alfaxalone induction, isoflurane gas) are recommended. Pre-oxygenate for 5-10 minutes prior to induction. Monitor for arrhythmias, hypotension, and hypoxia both intra and post-operatively and intervene as necessary. Mild IV fluid restriction is recommended to avoid fluid overload. Avoid heart rate stimulating drugs such as atropine unless clinically indicated.
- Monitor for development of a cough, labored breathing, exercise intolerance or collapse episodes.

BREED

Brittany Spaniel

SEX

Female Spayed

AGE

12 years

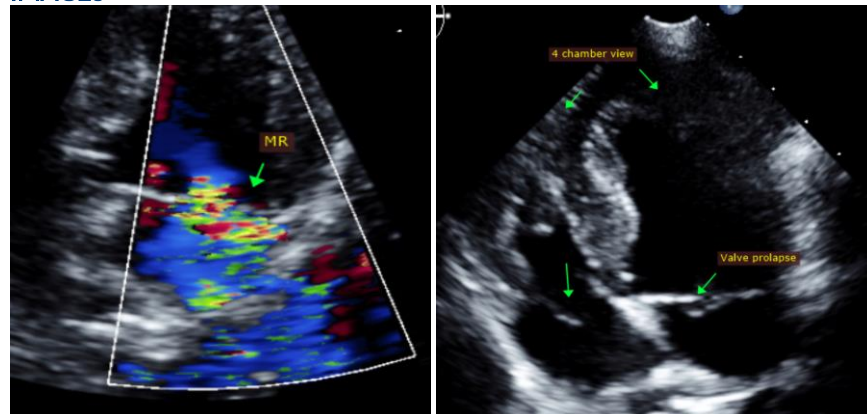
PLAN

- Recommend conservative monitoring with a recheck echocardiogram in 6 months, sooner if any development of clinical signs.

WEIGHT

42.1lbs

IMAGES



INTERPRETED BY

Maggie Machen
Lamy, DVM
DACVIM (Cardiology)

**IMAGING
PERFORMED BY**

Pamela Harrigan,
RDCS

HOSPITAL NAME

Mass Veterinary
Services

The information and recommendations provided are based on the images presented by the referring veterinarian. No evaluation can be communicated regarding pathology that was not visible in the image/video clips provided.

REFERRING VET

Dr. Masloski

Thank you for this referral. This report was generated using transcription software, and minor dictation errors may be present. If the clinical or image interpretation does not parallel your findings or if I can be of any further assistance, please contact me.

INVOICE

26374

Maggie Machen Lamy, DVM
Diplomate of the American College of Veterinary Internal Medicine (Cardiology)
info@sonopath.com

DATE

9/14/22

Echocardiogram performed by:

Pamela Harrigan, RDCS
Pet Animal Ultrasound Service (4paus.com)